

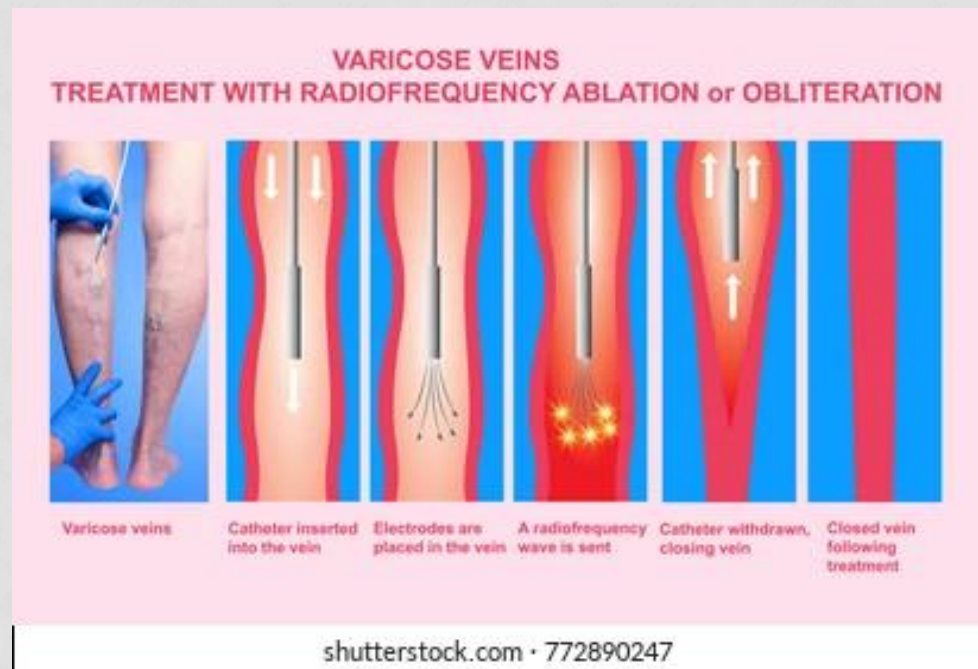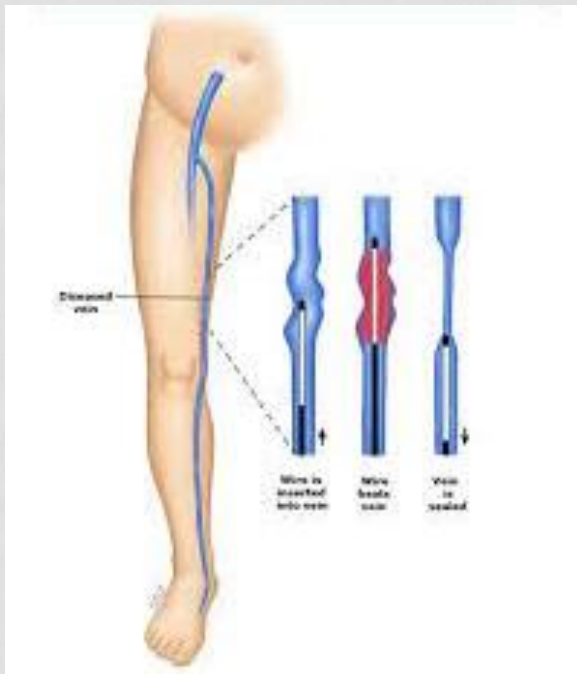
CASE DISCUSSION IN VENOUS LEG ULCER

Rattana Piancharoensin, APN



Case Study: Recurrence of VLU

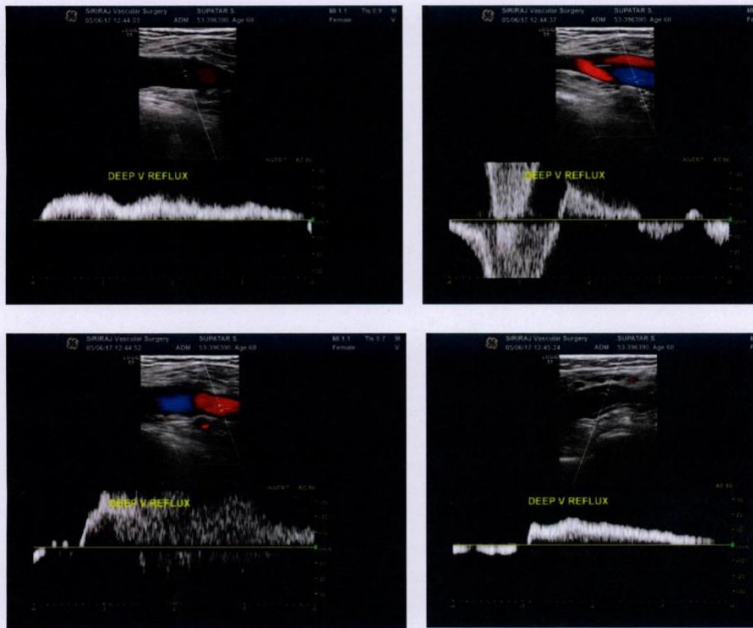
Female 64 years old with U/D of DM, HT, DLP
Known case CVI C5 Rt. leg
S/P RFA Rt. SSV on 01-Sep-2016



Duplex scan on 5-Jun-2017

Name: S., SUPATAR
Patient Id 53-396390

Perf.Physician:
Age 60



Finding

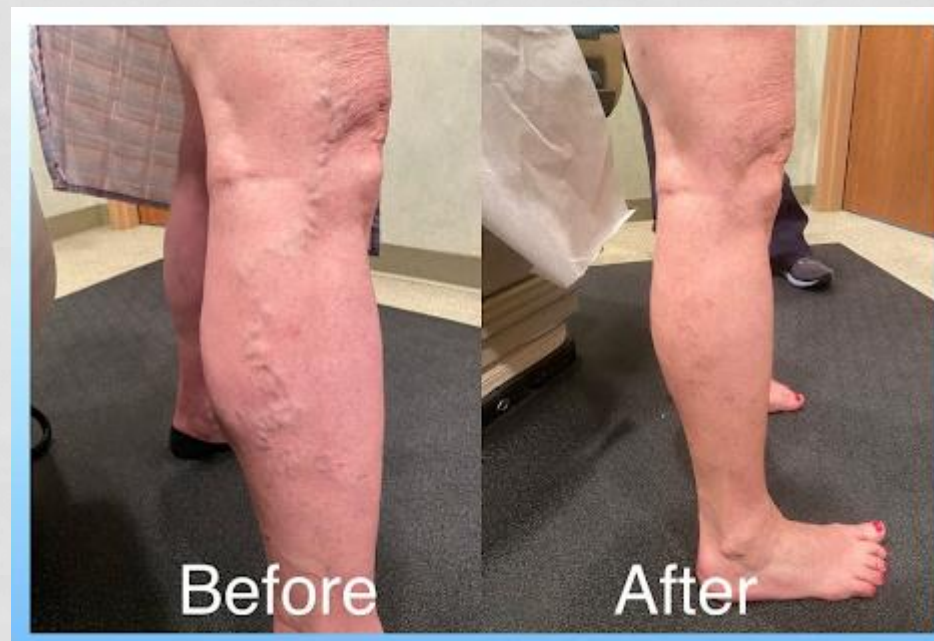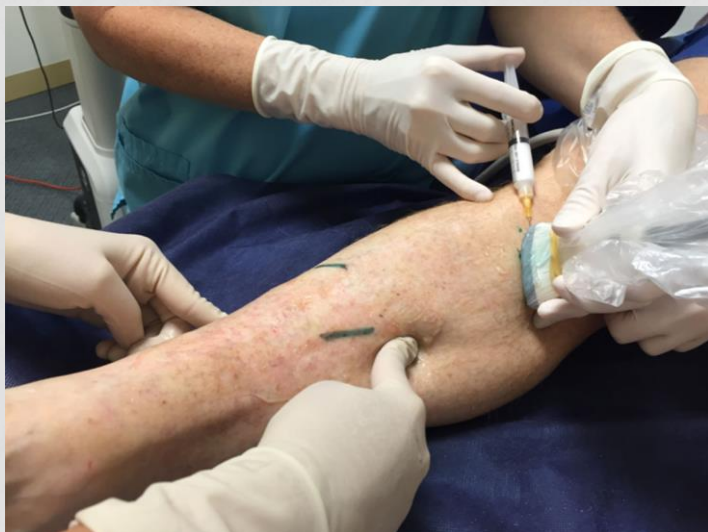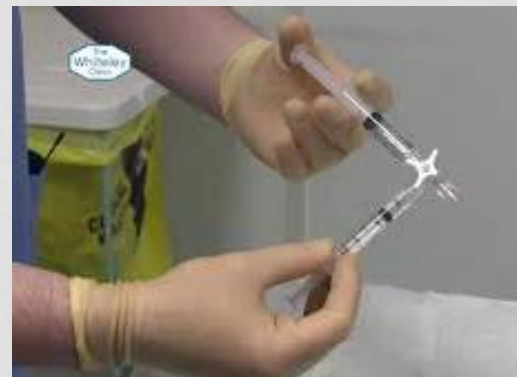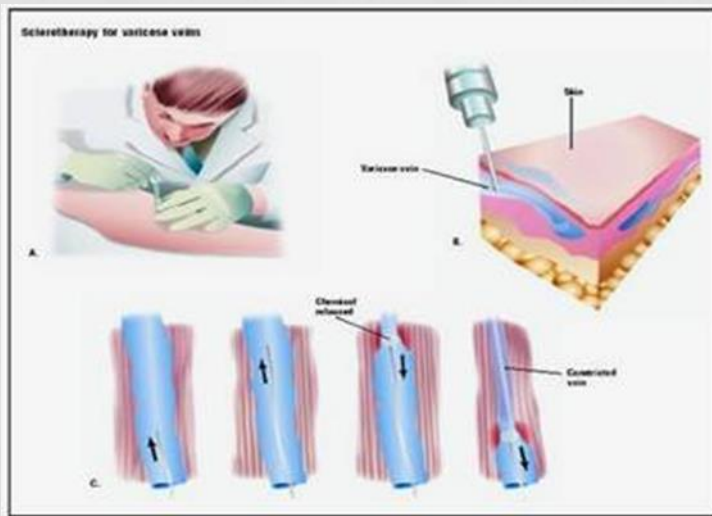
- * - Perforator reflux (มีงู/ลม)
- NO SSV reflux (occlude SSV)
- Not seen GSV (มีแผลที่ VLU)

Diagnosis

- * - Deep v. reflux at CFV, pop. v.
- Perforator reflux

พบ Perforator reflux : Ultrasound guide form sclerotherapy (24-Aug-2017)
: Healed VLU on 30-Oct-2017

Ultrasound guide form sclerotherapy (USGFS)



Recurrence VLU in next 3 years

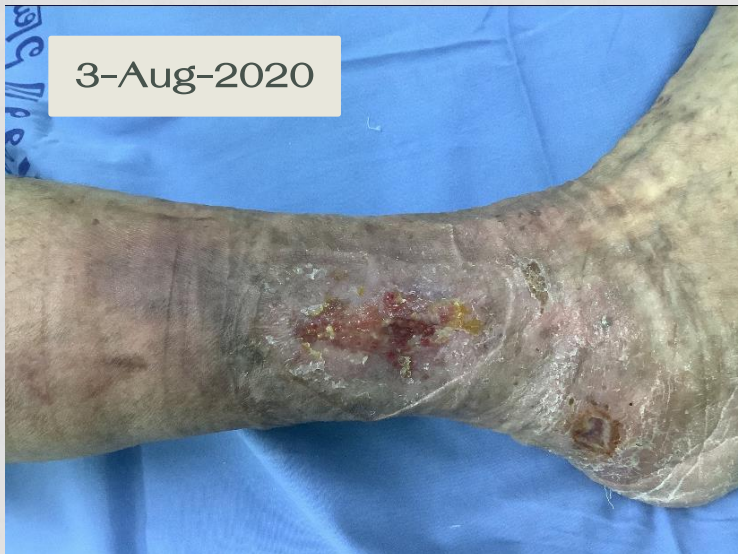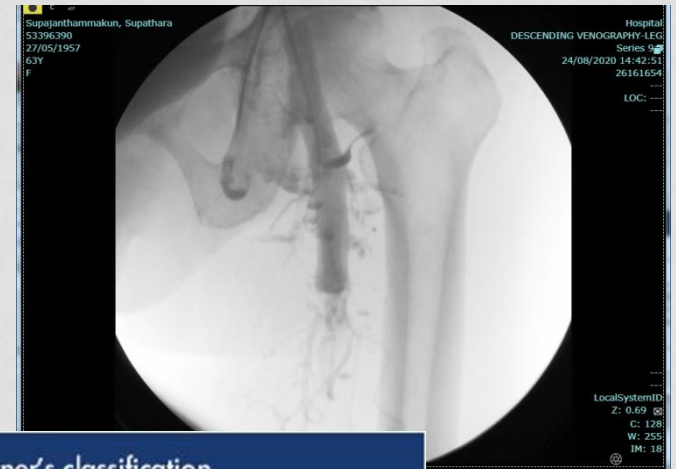Finding

- * - Perforator reflux (รั่วๆ/แอม)
- NO SSV reflux (occlude SSV)
- Not seen GSV (ไม่พบบน อัลตราซาวด์)

Diagnosis

- * - Deep v. reflux at CRV, pop. v.
- Perforator reflux

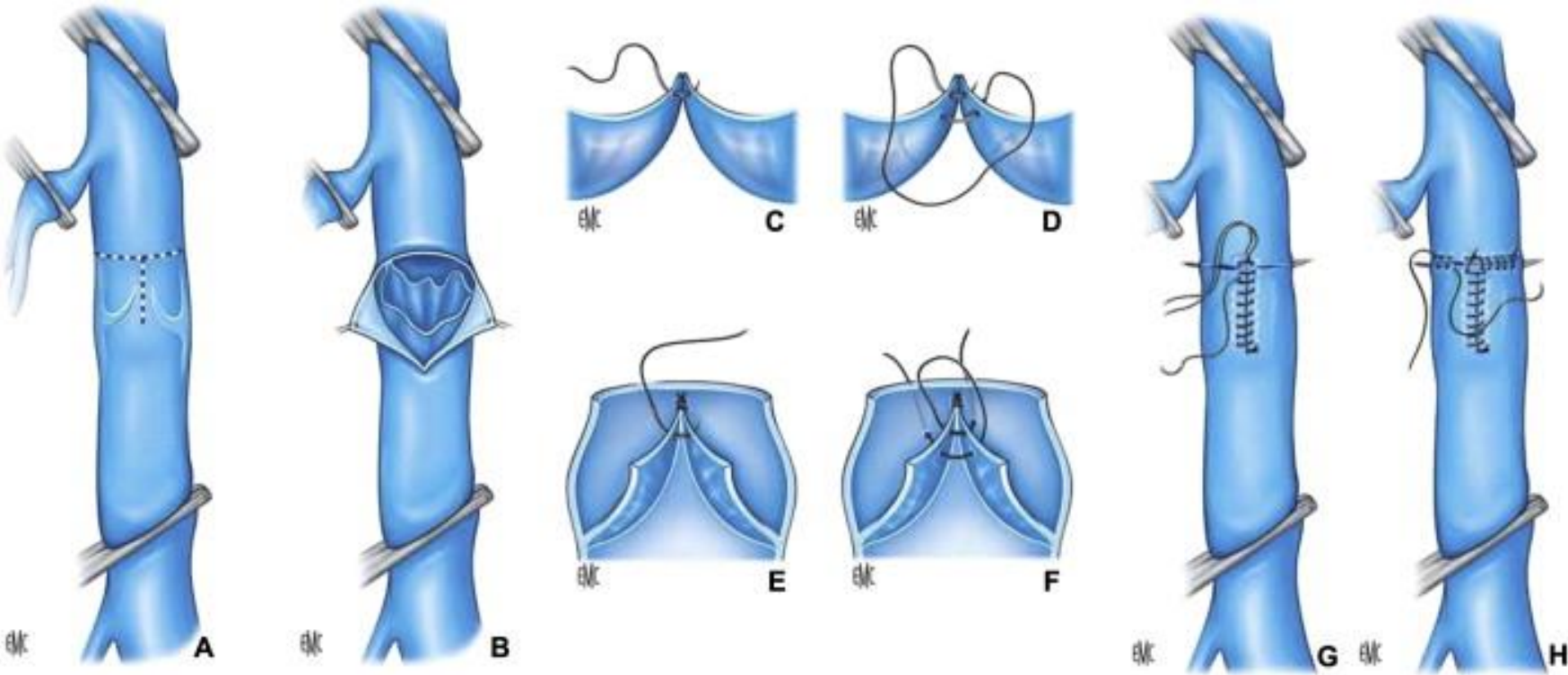
Descending Venography (24-Aug-2020)



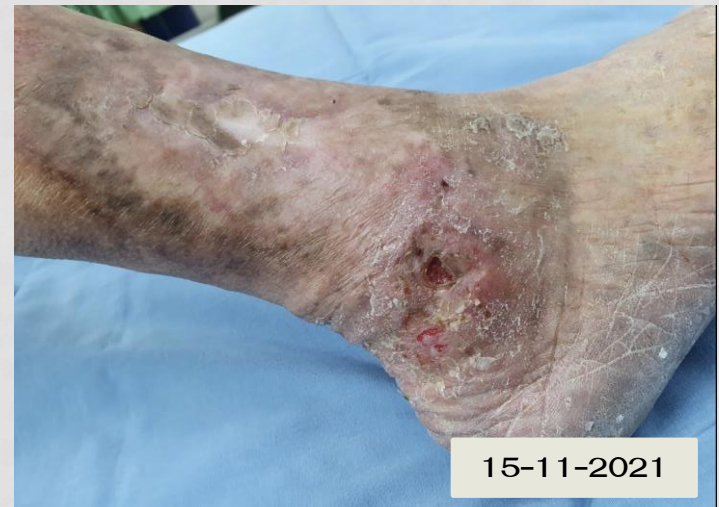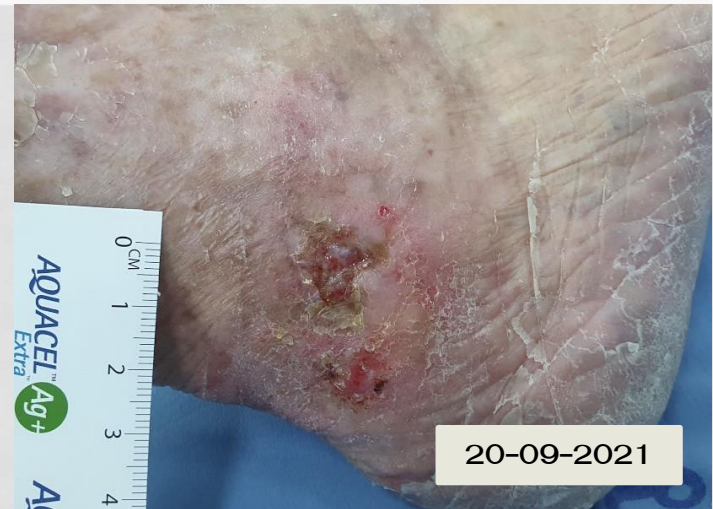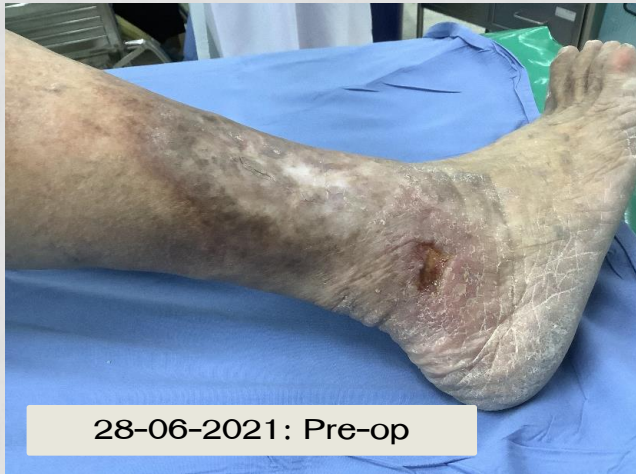Kistner's classification

- Grade 0: No reflux
- Grade 1: Reflux of the upper thigh
- Grade 2: Reflux in the lower thigh to the popliteal level
- Grade 3: Reflux below the popliteal level into the upper calf
- Grade 4: Reflux to the ankle

Internal Valvuloplasty (19-Aug-2021)



Result of Surgery



Prevention of VLU Recurrence



ในฐานะ ET nurse
ท่านจะแนะนำการปฏิบัติตัวอย่างไร
เพื่อป้องกันการเกิดแผลซ้ำ