

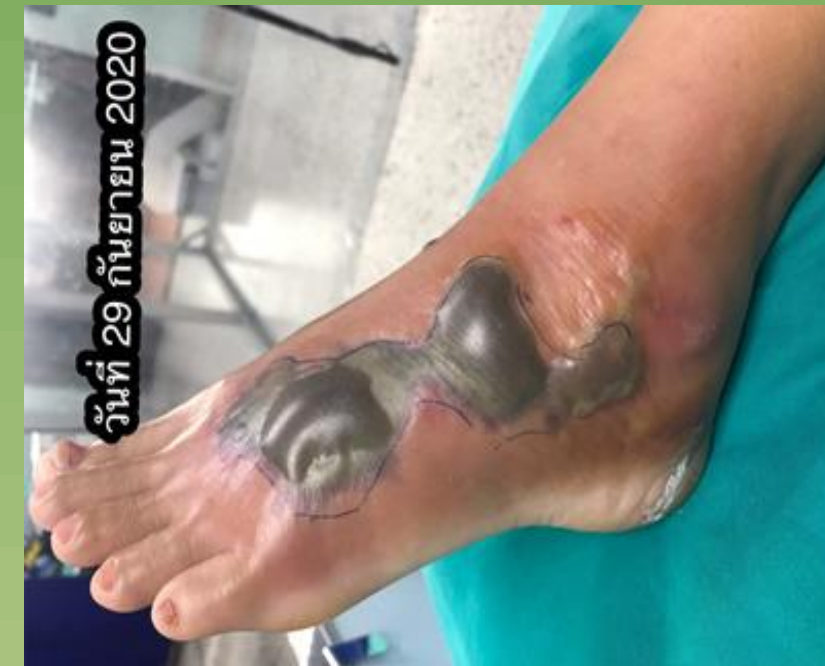

Cobra Bite Wound Management

Mrs. Supaporn Wongnikorn
Chaophraya Abhaibhubejhr Hospital

Background

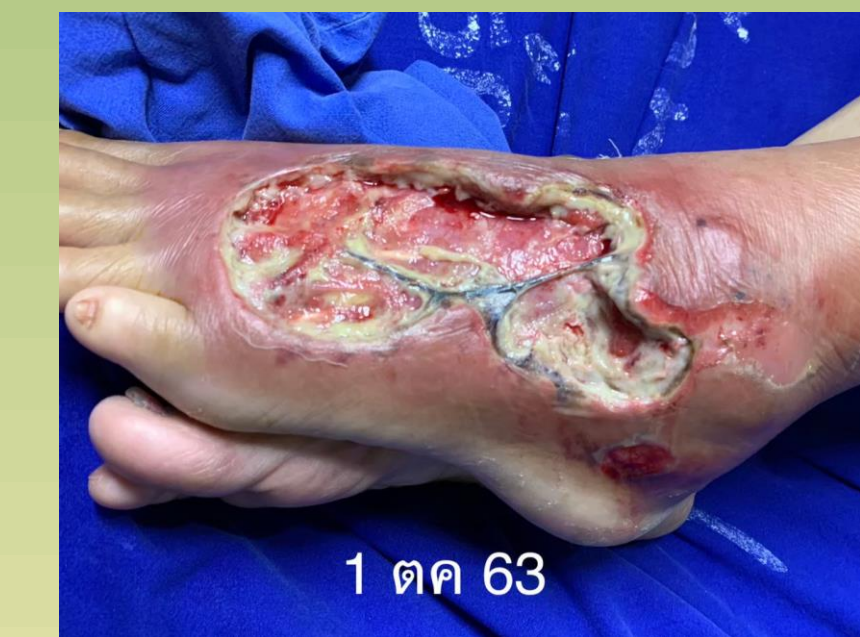Cytotoxins in cobra venom are the main cause of wound tissue damage/necrosis. Damaged vascular tissue causes swelling, hemorrhagic blebs in rigid space. Swelling can depress blood flow, causing compartment syndrome. Pathogens in the mouth and snake fangs cause a high risk of wound infection. The patient will have a lot of pain. These causes require patients to stay in hospital for a long time. Therefore, the wound care of cobra bite patients has been studied as a guideline for more effective wound care of patients. Thai Female ages 54 years old Dx. Cobra bite Lt foot. 25 Sep 2020 : admit Internal Medicine Department. 28 Sep 2020 : consult Surgery for Cobra bite with Necrotizing Fasciitis Lt foot. 29 Sep 2020 : Excisional Debridement Surgery After surgery, the wound is infected with inflammation and necrosis. In the initial stage, treat the wound with Wet dressing with Nss and Sillversulfadiazine bid. The patient has a lot of pain. Therefore, the wound care was adjusted using advanced wound dressing. It was found that the wound pain was reduced, and the wound healed faster. It can reduce patient costs and shorten hospital stays



Results

1. After Excisional Debridement, there is a wound size 12x5x0.8 CM. 95% slough 5% granulation. After dressing in the first 1-2 weeks, slough decreases by 90%, granulation 5% slough.
2. Week 3: The wound is 95% better, granulation 5% slough, patient discharge, and Dressing 3-5 days at home.
3. Week 5: 100% granulation wound edge Epithelialization mild Exudate
4. Week 8: The wound has healed.


Studies have shown that Wound management and wound bed preparation is important. Advance wound dressing is used to help the wound heal faster. It can reduce patient pain, cost and shorten hospital stay.



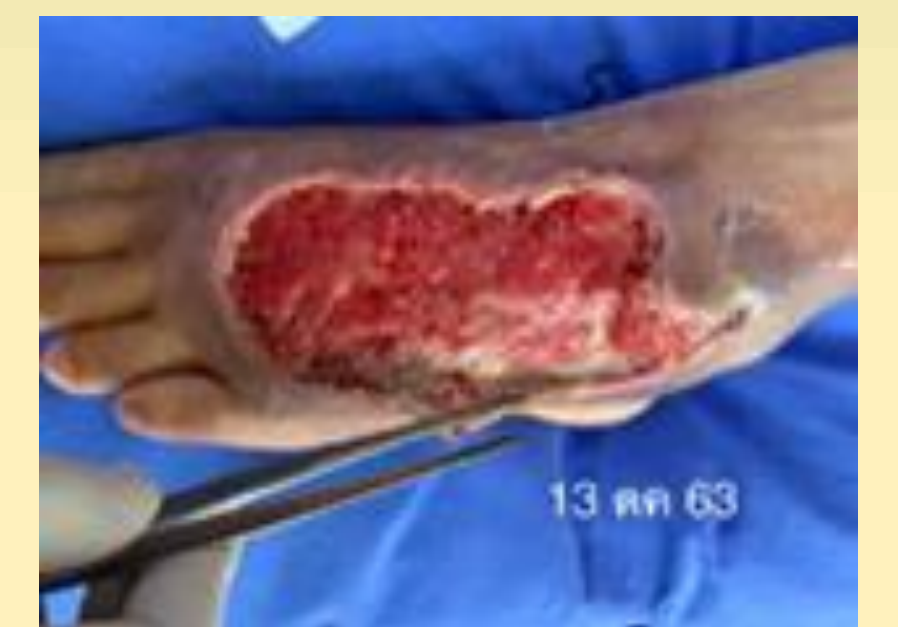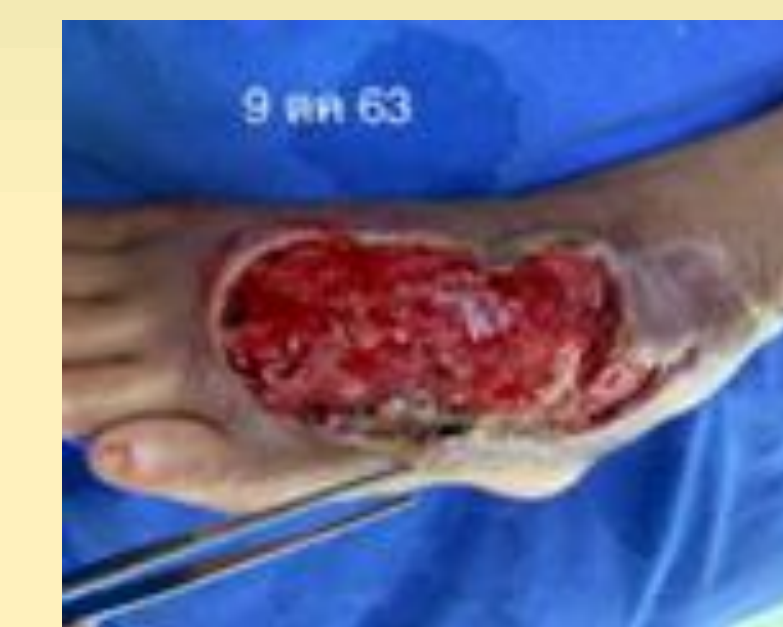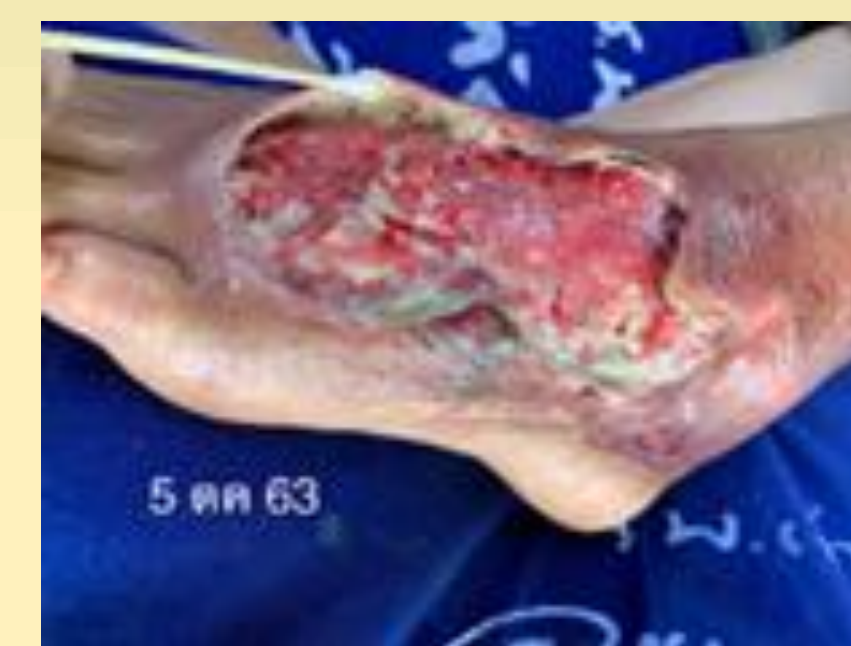Day 1-3

Methodology and Materials

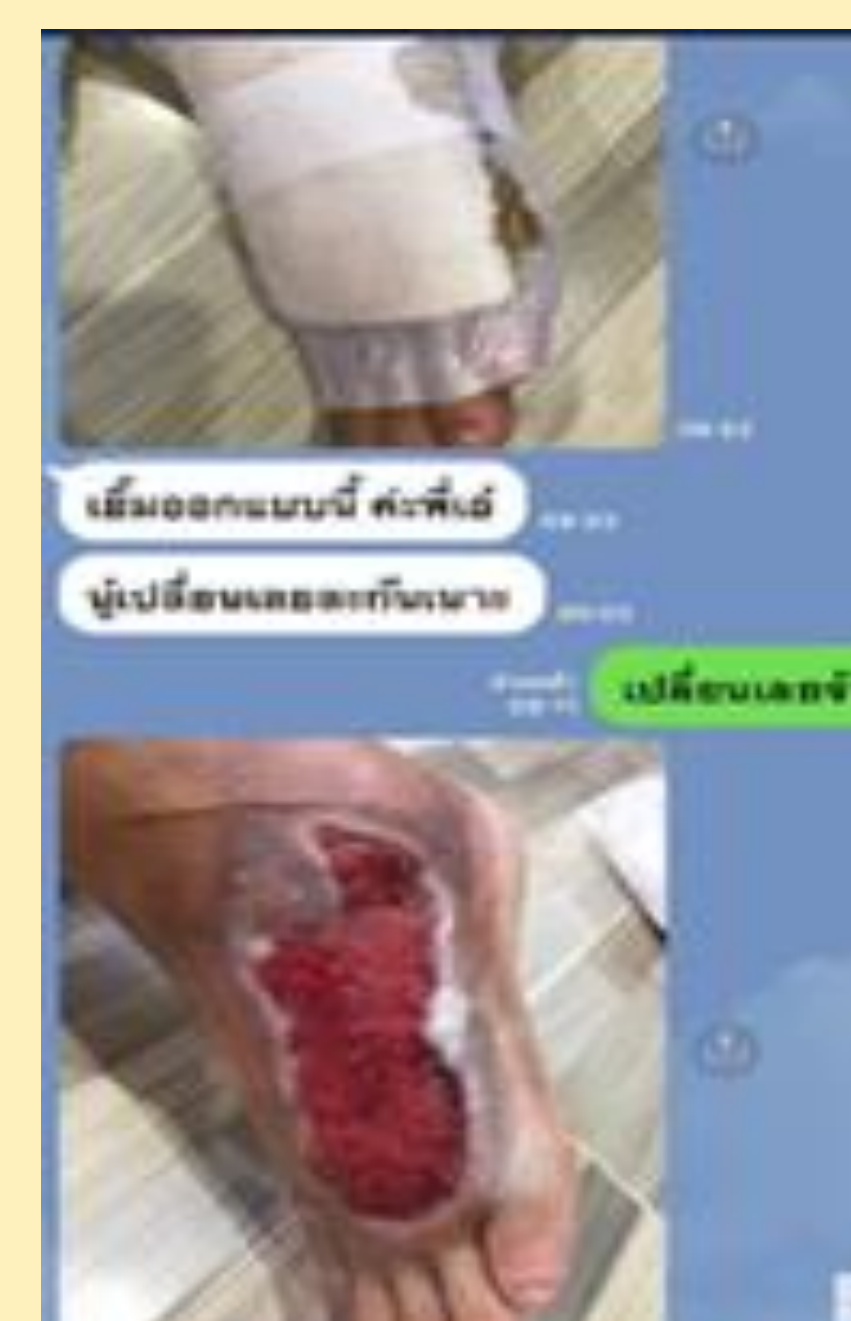1. Wound management includes the first 1-3 days Wet dressing with Nss and Sillversulfadiazine bid. The patient has a lot of pain. Day 4 Change Wet dressing: cleansing with Nss and socking Polyhexanine-Betaine 15 minutes and apply silver alginate matrix paste for treatment local infection and cover with gauze change every day 2 week.



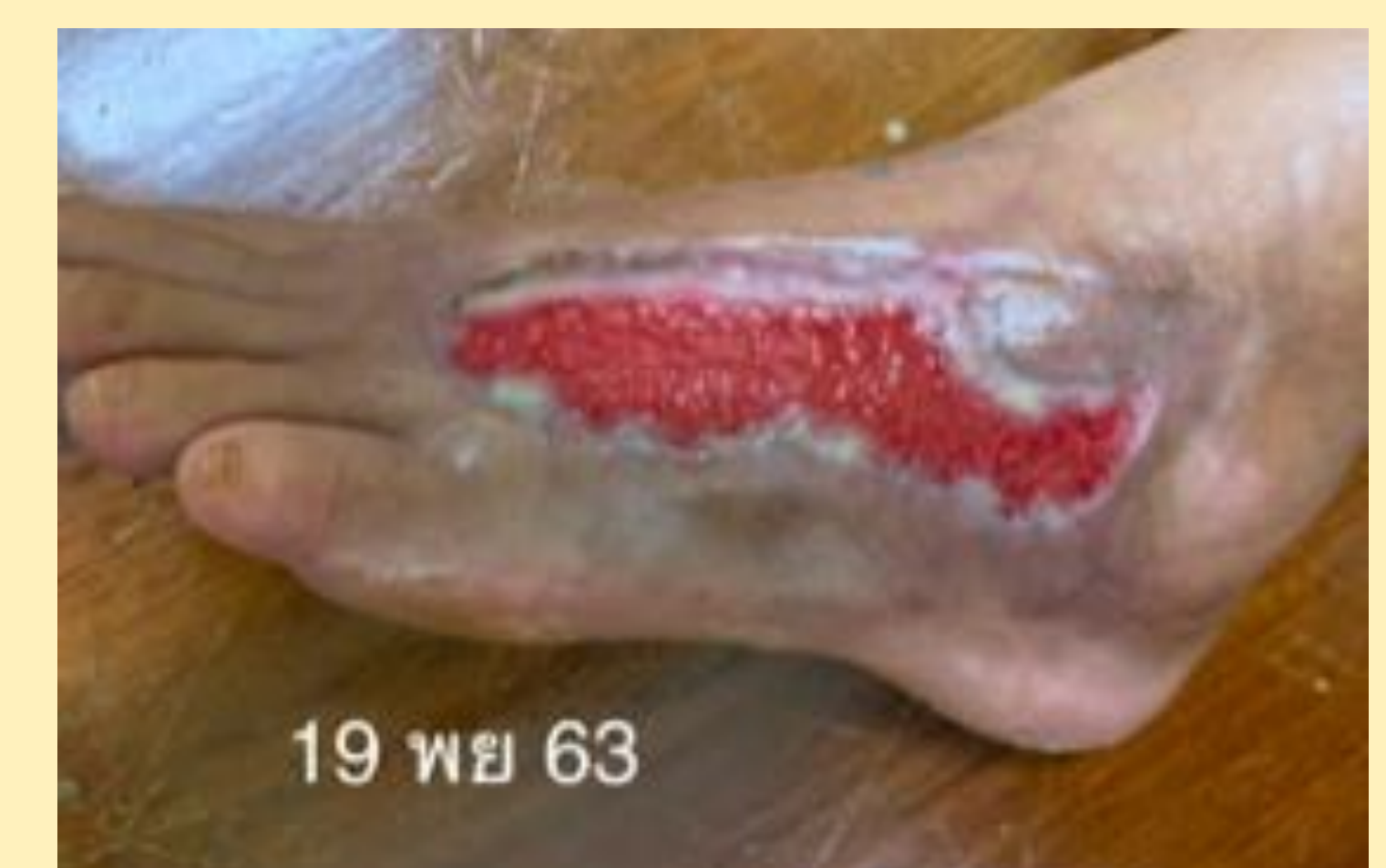2. Ask the patient lie down with legs elevated and do ankle pumping exercises.
3. After 2 weeks, the wound healed 90%, granulation 10% slough dressing with Nss and socking Polyhexanine-Betaine 15 minutes and cover with silver alginate matrix foam change every 3-5 day at home.
4. Week 5, 100% granulation wound edge Epithelialization dressing with Nss and socking Polyhexanine-Betaine 15 minutes and cover with foam change every 5 days at home.



Day 4 – Week 2



Week 3



Week 5

Conclusion

Wound management and wound bed preparation in infected Cobra Bite wounds are very important. In the Inflammations phase, the patient experiences severe wound pain. Removing Advance wound dressing can help slough off easily and reduce wound infection. Patients have less pain in the wound and make the wound heal faster. It also reduces the length of hospital stay and decreases the total cost of patient and nursing workload.

References

1. วิชัย สนิธิเมือง. (2560). แผนงูกัดในเด็ก:ปัจจัยเสี่ยงของผลการรักษาด้วยการผ่าตัด. มหราชชนนศรีธรรมราชเวชสาร,1 (1). <http://www.mecnst.com/NSTMJ/file content/202102061145374303.pdf>.
2. ศูนย์พิษวิทยารามาธิบดี Poison Center. (2018). พิษงู COMMON POISONING. <https://med.mahidol.ac.th/poisoncenter/th/poison-cov/snake>.
3. Heng Yeh, Shi-Ying Gao and Chih-Chuan Lin. (2021). Wound Infections from Taiwan Cobra (Naja atra) Bites: Determining Bacteriology, Antibiotic Susceptibility, and the Use of Antibiotics-A Cobra BITE Study Toxins. <https://doi.org/10.3390/toxins13030183>.

Week 8

